

CASE REPORT

Acute Type A Dissection and Acute Inferior MI Complicating Aortic Coarctation: A Case Report

Mohsen Taghavi Shavazi¹, Ahmad Amouzesi², Toba Kazemi³✉,
Alireza Ehsanbakhsh⁴

¹ Cardiovascular Diseases Research Center, Assistant Professor of Cardiology, Birjand University of Medical Sciences, Birjand, Iran

² Cardiovascular Diseases Research Center, Assistant Professor of Cardiosurgery, Birjand University of Medical Sciences, Birjand, Iran

³ Cardiovascular Diseases Research Center, Professor of Cardiology, Birjand University of Medical Sciences, Birjand, Iran.

⁴ Cardiovascular Diseases Research Center, Associate Professor of Radiology, Birjand University of Medical Sciences, Birjand, Iran

Received: September 23, 2016 Revised: February 18, 2017 Accepted: January 28, 2017

Abstract

Aortic coarctation is a rare but dangerous condition. Presence of aortic dissection in addition to coarctation is significantly rarer and more life-threatening. Here, we present a case of acute inferior MI due to aortic dissection complicating a native aortic coarctation.

A 17-year-old boy was admitted to our emergency department due to severe chest pain and loss of consciousness. His electrocardiogram showed ST elevations in Inferior leads proposing an inferior MI. Further evaluations revealed that the patient had been suffering from an underlying aortic coarctation complicated by an acute aortic dissection.

For every young person with symptoms of acute coronary syndrome, aortic dissection should be considered as a potentially fatal differential diagnosis. Coexistence of aortic coarctation, as an underlying and exacerbating factor, should be assessed using appropriate imaging modalities whenever suspected.

Key Words: Aortic Dissection; Aortic Coarctation; Acute Myocardial Infarction

Introduction

Coarctation of the aorta is a rare condition and if left untreated, it can lead to severe morbidity or fatality [1]. Aortic coarctation complicated by acute aortic dissection is a significantly rarer situation and can be life-threatening. We here report a rare case of acute inferior MI due to type A aortic dissection complicating a native aortic coarctation.

Cases

In July 2015, a 17-year old boy administered to our emergency department with complaints of

chest pain and loss of consciousness. The pain, which was severe and tearing, had acutely started 4 hours before admission, while the patient was swimming. Immediately after the beginning of pain, the patient had lost his consciousness as well as his urine and bowel continence. He had a history of an unknown cardiac disorder which had been diagnosed at the age of 7. At that time, he was a candidate for surgical treatment, but his family had refused it for personal reasons. He had no history of other cardiovascular disorders. He had not taken any medication recently, had not drunk alcohol or smoked. At the time of admission, he had regained

©2015 Journal of Surgery and Trauma

Tel: +985632381203

Fax: +985632440488

Po Bax 97175-379

Email: jsurgery@bums.ac.ir



✉ Correspondence to:

Toba Kazemi, Cardiovascular Diseases Research Center, Professor of Cardiology, Birjand University of Medical Sciences, Birjand, Iran;

Telephone Number: 0985632433004

Email Address: drtooba.kazemi@gmail.com

consciousness but he was confused. Physical examination revealed a blood pressure of 125/75 mmHg. Pulse rate was 110 beats/minute regular in upper extremity, and lower extremity pulses were undetectable. Other physical findings were unremarkable. His 12-lead electrocardiogram (Figure 1) showed regular sinus rhythm, left ventricular hypertrophy, pathological Q wave and ST segment elevation in inferior leads. Laboratory results did not show signs of typical myocardial necrosis. Serum cholesterol, LDL, HDL and triglyceride levels were found to be in normal ranges. Emergent chest radiography (AP view) revealed an increased Cardio-Thoracic Ratio (CTR). Transthoracic echocardiography showed an LV ejection-fraction of 55%, mild MR, moderately severe AI, aortic root dilation (47 mm), and a visible dissection flap in ascending aorta.

Multidetector computed tomographic (CT) contrast angiography of the mediastinum (Figure 2) showed a post-ductal aortic coarctation with a

4-mm stenotic segment. Significant dilation was noted in the ascending Aorta (67×82 mm), beginning from aortic root (56×63 mm) and extending to the arch (26×15 mm). A type A aortic dissection with a thin flap in aortic root extending to mid ascending aorta was detected. The flap was also extended to the sinotubular junction and RCA. Marked Vascular collateral formation and dilation of both internal mammary arteries (5 mm) was noted. A periaortic hematoma was also seen on CT images.

Based on these findings, a diagnosis of acute type A dissection and consequent inferior MI complicating aortic coarctation was considered. The patient underwent Bentall operation involving composite graft replacement of the aortic valve, aortic root, and ascending aorta, with re-implantation of the coronary arteries into the graft. SVG was grafted to RCA and aorta. He did well in his follow-up and discharged after 15 days.

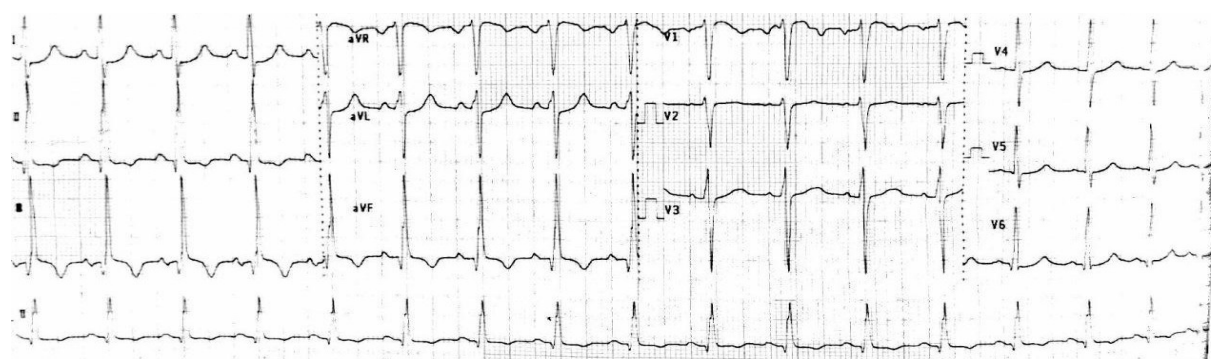


Figure 1. 12-lead electrocardiogram showing regular sinus rhythm, LVH and pathological Q wave and ST elevation in inferior leads

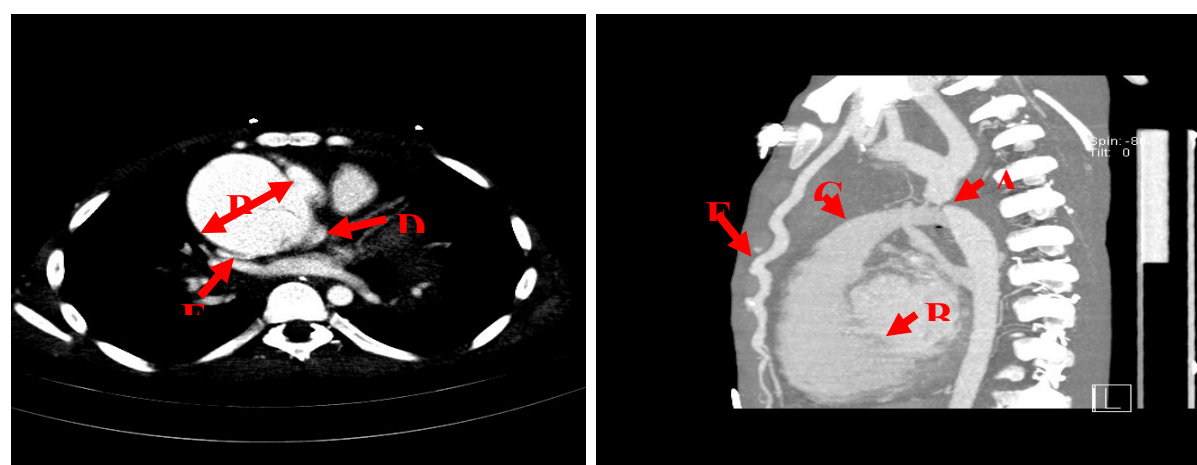


Figure 2. CT angiography of the mediastinum showing a postductal aortic coarctation with a 4-mm stenotic segment (A) - Significant dilation in ascending Aorta (67×82 mm) beginning from aortic root (56×63 mm) (B) and extending to the arch (26×15 mm) (C) - Type A aortic dissection with a thin flap in aortic root extending to mid ascending aorta; the flap is also extended to the posterior sinotubular junction (D) and RCA (E)- Marked vascular collateral formation and dilation of internal mammary artery (5 mm) (F).

Discussion

The combination of aortic coarctation, acute aortic dissection and inferior MI in a young patient with no cardiovascular risk factor is a very rare and serious situation and to our knowledge, there has been no similar reports. In such a situation, a rapid diagnosis and an appropriate management can be crucial and life-saving.

Most individuals with coarctation of aorta usually have nonspecific symptoms, related either to upper extremity hypertension (headaches) or to reduced blood supply for the lower extremities (exercise-induced claudication)[2]. Acute coronary syndrome manifestations in patients with aortic coarctation are seen more frequently than others. The leading cause is atherosclerosis due to hypertension and endothelial dysfunction. Another mechanism for coronary artery disease with coarctation of aorta is activation of the sympathetic nervous system. Sympathetic activation increases myocardial contractility and increases systemic pressure that helps maintain perfusion of the descending aorta and abdominal organs [3]. In this situation, the addition of coarctation further increases both left ventricular afterload and myocardial oxygen demand.

Another cause of acute coronary syndrome in people with coarctation, which must be considered as an important differential diagnosis, is aortic dissection with a flap extending to coronary arteries. This devastating event occurs in 1% to 5% of patients with aortic dissection [4, 5]. Based on reports, aortic dissection, as a rare etiology of acute coronary syndrome, is often missed in a patient with ST segment elevation on initial ECGs [6]. Asouhidou et al [7] revealed that the initial misdiagnosis of aortic dissection was about 30%, in which 15 out of 50 patients with aortic dissection were misdiagnosed as myocardial infarction (12 patients) and cerebral infarction (three patients). The misdiagnosis is less likely to happen in young cases with no atherosclerosis risk factor because other etiologies are usually taken into account and studied. However, old patients with atherosclerosis risk factor are at high risk of misdiagnosis, which can lead to inappropriate treatment with antiplatelet, antithrombin, and thrombolytic agents. While the use of thrombolytic and anticoagulant agents might temporarily improve the signs of myocardial infarction, the mortality rate climbs to over 70% from approximately 24% as administration of thrombolytic drugs mostly cause hemorrhage into the pericardial sac causing pericardial tamponade [8].

Type A aortic dissection arises above the right sinus, and retrograde extension into the aortic root more likely affects the right coronary artery than the left, as it did in the current case. The patient presented with a chest pain and ST segment elevation in EKG, common signs of myocardial infarction, which could be initially misdiagnosed as myocardial infarction and inappropriately administrated with thrombolytic and anticoagulant agents. Fortunately, the patient was examined with a series of imaging technology and treated successfully with surgery, which also confirmed the diagnosis.

Conclusions

Our findings suggest that acute aortic dissection should always be considered as an important differential diagnosis in patients presenting with symptoms of acute coronary syndrome. Moreover, coexistence of aortic coarctation as an underling and exacerbating factor should be taken into consideration. If there is a high index of suspicion, it is wise to consider further imaging studies as the recommendation of the associated guidelines.

References

1. Singh S, Hakim FA, Sharma A, Roy RR, Panse PM, Chandrasekaran K, Alegria JR, Mookadam F. Hypoplasia, Pseudocoarctation and Coarctation of the Aorta-A Systematic Review. *Heart Lung Circ.* 2015;24(2):110-8.
2. Torok RD, Campbell MJ, Fleming GA, Hill KD. Coarctation of the aorta: Management from infancy to adulthood. *World J Cardiol.* 2015;7(11):765-75.
3. Xiong D, Chen Z, Xu W. Coarctation of the aorta diagnosed by cardiac computed tomography angiography in a 49-year-old man presenting with acute myocardial infarction. *Int J Cardiovasc Imaging.* 2016;32(4):655-7.
4. Kar-mun CW, Schneider JI. High-risk chief complaints I: chest pain—the big three. *Emerg Med Clin North Am.* 2009;27(4):685-712.
5. Luo JL, Wu CK, Lin YH, Kao HL, Lin MS, Ho YL, Chen MF, Chao CL. Type A aortic dissection manifesting as acute myocardial infarction: still a lesson to learn. *Acta Cardiol.* 2009;64(4):499-504.
6. Motwani M, Arya S, Poon C, Schmitt M. Aortic Coarctation Presenting as Pseudoinfarction. *J Am Coll Cardiol.* 2011;57(3):376.
7. Asouhidou I, Asteri T. Acute aortic dissection: be aware of misdiagnosis. *BMC Res Notes.* 2009;2(1):25.
8. Jović Z, Obradović S, Đenić N, Mladenović Z, Đurić P, Spasić M, Tavčiovski D. Does thrombolytic therapy harm or help in ST elevation myocardial infarction (STEMI) caused by the spontaneous coronary dissection?. *Vojnosanit Pregl.* 2015;72(6):536-40.