

CASE REPORT

A case report of Pancoast tumor presenting as cervical radiculopathy

Reza Abdi¹✉, Elahe Bijari²

¹ Department of Pediatric Orthopedics, Faculty of Medicine, Birjand University of Medical Sciences, Birjand, Iran.

² Student Research Committee, Medical Student, Faculty of Medicine, Birjand University of medical science, Birjand, Iran.

Received: October 8, 2016 Revised: November 2, 2016 Accepted: November 26, 2016

Abstract

Pancoast tumor accounts for 3%-5% of all non-small cell lung carcinomas. This tumor has a distinct clinical presentation through local invasion and the resulting clinical entity called Pancoast syndrome. This syndrome includes severe shoulder pain, arm pain, and Horner's syndrome and atrophy of forearm and hand muscles. The differential diagnosis of arm and shoulder pain is extensive. Thoracic outlet syndrome and cervical disk disease are commonly mistaken for the Pancoast syndrome in the early clinical course. Diagnosis of Pancoast tumor is often late, and misdiagnosis is a common problem that can affect the prognosis. Therefore, Pancoast tumor should always be considered in differential diagnosis of radicular pain of the upper extremity.

We report a case of 55-year-old man who was admitted with right side severe pain in the back of the neck, shoulder and arm with numbness and tingling sensation in the medial aspect of the forearm and 4th and 5th fingers. These symptoms had initiated from 17 months ago, and the patient was treated for cervical discopathy and frozen shoulder.

Key Words: Pancoast Tumor; Cervical Radiculopathy; Frozen Shoulder

Introduction

Pancoast tumor is a primary carcinoma occurring at the apex of the lungs, in the area of the superior sulcus [1]. These tumors account for 3% to 5% of all non-small cell lung carcinomas [2]. The symptoms of the tumors are related to their invasion of the near structures such as brachial plexus, intercostal nerves, sympathetic ganglions, first and second ribs, and subclavian arteries and veins [3, 4]. Back pain of the shoulder is the most common symptoms of Pancoast tumors [5-8]. While cough, dyspnea, and hemoptysis are often associated with lung cancer, they are not common in Pancoast tumors [2, 6]. The other symptoms in these patients include arm pain, neck pain, hand atrophy, paraesthesia in 4th and 5th fingers and

Horner's syndrome [3-5, 9]. Because the symptoms are vague, they can be mistaken for a more frequent condition affecting the neck and shoulder, and thereby delayed diagnosis can happen [3]. Pancoast tumor is a treatable disease, but the survival depends on how quickly the proper diagnosis is established [1]. Delayed diagnosis of Pancoast tumor usually affects the treatment plan and patient prognosis [9].

We report a case of Pancoast tumor misdiagnosed as cervical discopathy and frozen shoulder for 17 months.

©2015 Journal of Surgery and Trauma

Tel: +985632381203

Fax: +985632440488

Po Bax 97175-379

Email: jsurgery@bums.ac.ir



✉ Correspondence to:

Reza Abdi, Assistant Professor of Pediatric Orthopedics, Emam Reza Hospital, Department of Pediatric Orthopedics, Faculty of Medicine, Birjand University of Medical Sciences, Birjand, Iran ;
Telephone Number: 0985632226777
Email Address: reza1352abdi@gmail.com

Cases

A 55-year-old man presented to the orthopedic clinic with a chief complaint of right side progressive back pain of the shoulder and the neck that spread to the medial arm and forearm. The pain started 17 months ago when the patient visited with a complaint of constant pain at the anterior wall of the right hemithorax for the first time. The patient did not have respiratory signs such as cough, dyspnea, and hemoptysis. In AP chest radiography [Figure1], mild pulmonary hyperinflation had been reported.

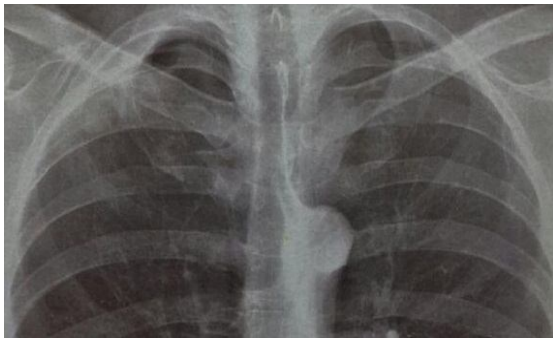


Figure 1: The upper half of AP view chest X-ray. There is a small homogenous shadow in the apical region of the right lung.

He reported right side progressive pain of shoulder and the back of the neck for one year after his first symptoms. He had methylprednisolone subacromial injection with a frozen shoulder misdiagnosis and used NSAIDs, other painkillers, and herbals to control his pain. He was also treated for a cervical discopathy that was reported in MRI for several months [Figure 2].

Seventeen months after his first symptoms, he was admitted to our clinic with a chief complaint of severe and excruciating back pain of the right shoulder and limited ROM of the shoulder. Also he was experiencing numbness and tingling sensation in the right medial aspect of the forearm, and 4th and 5th fingers. In the previous chest X-rays, a doubtful homogenous opaque shadow near the second rib was seen retrogradely [Figure3]. However, now a prominent homogenous opaque shadow existed in the apical region [Figure 4], leading to increased suspicion of the apical tumor of the lung.

The bone scan showed bone lesions with osteoblastic reaction in the posterior part of the right 2th rib. CT scan revealed an irregular, homogenous mass of size 60*45*50mm with soft tissue density within the right apical region destructing the first and second ribs [Figure 5 and 6].

He had a 10 pack-year history of smoking for ten years. In the laboratory test, high levels of ALP (326), LDH (660), and positive 3+ CRP were reported.

The diagnosis of Pancoast tumor was certain and confirmed by CT guided FNA.

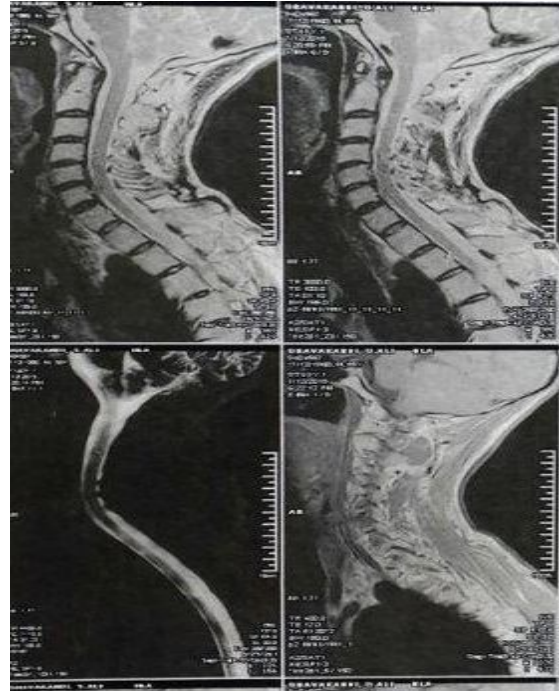

Figure 2: He was treated for a cervical discopathy.

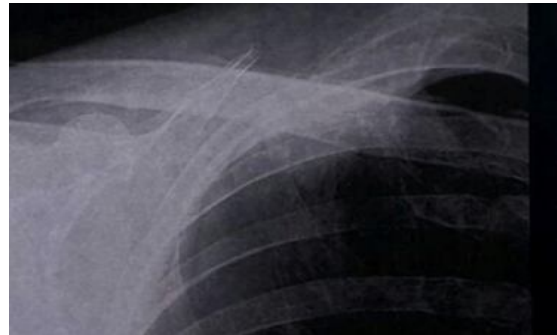

Figure 3: A doubtful homogenous opaque shadow near the right second rib

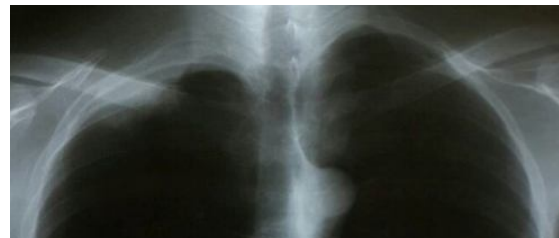

Figure 4: A prominent homogenous opaque shadow in the right apical region

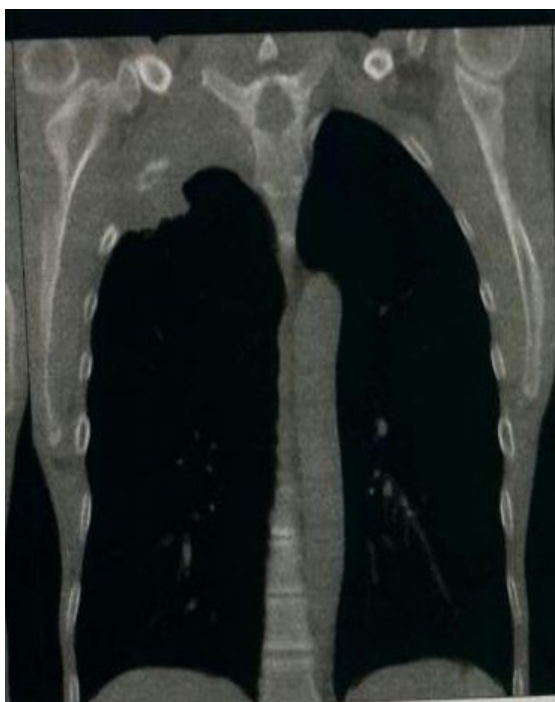

Figure 5: Coronal reformatted CT image shows the right apical tumor invading the chest wall and first and second ribs

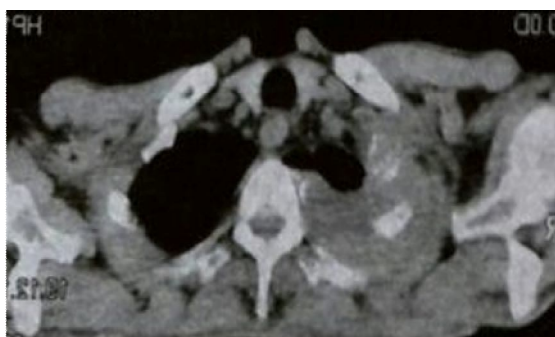

Figure 6: Axial CT image shows a homogenous lung mass in the right apical region destroyed the adjacent ribs

The patient did not have any respiratory symptoms and Horner's syndrome at the time of diagnosis. He just complained of asthenia and 6 kg weight loss in the last 6 months. A tissue diagnosis of the tumor via CT guided FNA showed bronchogenic adenocarcinoma, and the pain was decreased significantly after chemotherapy.

Discussion

In 1924, Henry Pancoast described the Pancoast syndrome for the first time [4]. Typically, one or more of the following symptoms characterizes the syndrome:

- Severe pain of ipsilateral shoulder that radiates to the neck, axilla, chest wall, and medial aspect of

the arm and forearm, along with the distribution of the ulnar nerve.

- Horner's syndrome (miosis, ptosis, anhidrosis)
- Weakness and atrophy of the intrinsic muscles of the hand.
- Upper arm edema [3-4].

However, cough, dyspnea and hemoptysis signs, which are often associated with lung cancers, are not common in Pancoast tumors [5, 6].

In this case, the first symptom was anterior chest wall pain and the right side shoulder pain, followed by neck pain. However, there was a delay in the diagnosis of tumor, and the patient did not have any respiratory signs, Horner's syndrome, hand muscles atrophy or upper limb edema. The initial symptoms are most frequently musculoskeletal and the pulmonary symptoms are rare resulting in delayed diagnosis in the majority of the Pancoast tumors [1].

Most of the patients are treated under a presumptive diagnosis of the cervical spondylitis, shoulder bursitis, cervical disc herniation, frozen shoulder, and rotator cuff tear [1, 3, 6, 8, 9].

In this case, he was treated for cervical discopathy and frozen shoulder.

However, earlier detection or the suspicion of the diagnosis may be made by radiographic investigation. It can be missed, especially when the small apical cap or apical pleural thickening is the only findings [1, 4, 10].

In this case, we could see a small homogenous shadow in the apical region of the lung in the primary chest radiograph that was previously missed [Figure 1].

Thoracic CT scan is the most valuable method for the detection of Pancoast cancer [5]. It can exactly show the position and invasion of the tumor [11, 12]. Tissue diagnosis of the mass is usually made through a percutaneous CT-guided fine needle biopsy, which is successful in more than 90% of cases, making it the diagnostic modality of first choice [4]. Pancoast tumors include 95% of non-small-cell-lung-carcinomas, most commonly squamous cell (52%), followed by adenocarcinomas (23%), and large cell carcinomas (20%). Only about 5% of Pancoast tumors are small-cell [2].

Conclusion

Symptoms of Pancoast tumors may be vague and mistaken for a more frequent condition affecting the neck and shoulder, leading to delayed diagnosis as reported in some studies [6, 7, 9, 10].

Early diagnosis is crucial because the prognosis directly depends on the quick and

prompt treatment [10]. Physicians should maintain a high index of suspicion and consider Pancoast tumor in their differential diagnosis in the upper extremity pains.

In a patient who has a history of smoking with severe shoulder, neck and arm pain, which is unresponsive to treatment, the Pancoast tumor should be strongly considered.

References

1. Gupta MK, Dhunge K, Ahmad K, Rauniyar RK, Ansari S. Pancoast Tumor Masquerading as Cervical Spondylosis: a Case Report. *Nepal Journal of Medical Sciences*. 2013;2(2):184-6.
2. Setzer M, Robinson LA, Vrionis FD. Management of locally advanced Pancoast (superior sulcus) tumors with spine involvement. *Cancer Control*. 2014; 21(2):158-67.
3. Villas C, Collía A, Aquerreta D, Aristu J, Torre W, Díaz de Rada P, et al. Cervicobrachialgia and pancoast tumor: value of standard anteroposterior cervical radiographs in early diagnosis. *Orthopedics*. 2004; 27(10):1092-5.
4. Foroulis CN, Zarogoulidis P, Darwiche K, Katsikogiannis N, Machairiotis N, Karapantzios I, et al. Superior sulcus (Pancoast) tumors: current evidence on diagnosis and radical treatment. *J Thorac Dis*. 2013; 5 Suppl 4:S342-58.
5. Deng PB, Luo YY, Hu CP, Zhou LH. [Misdiagnosis of Pancoast cancer: analysis of 26 cases]. *Zhonghua Jie He He Hu Xi Za Zhi*. 2011;34(9):663-5. [Chinese]
6. Nam SO, Shin D, Park K, Kim TK, Kim HS. Pancoast Syndrome Accompanied by Rotator Cuff Tear. *Clin Should Elbow*. 2015;18(1):43-6.
7. Khoo SB. An 80-Year-Old Woman with Left Shoulder Pain. *Malays Fam Physician*. 2010;5(3):139-44.
8. Singhal S, Chowdhary GS. Pancoast tumor Misdiagnosed as ankylosing spondylitis. *J Clin Case Rep*. 2012; 2:187.
9. Bisbinas I, Langkamer VG. Pitfalls and delay in the diagnosis of Pancoast tumor presenting in orthopedic units. *Ann R Coll Surg Engl*. 1999;81(5):291-5.
10. Kim P, Hains F, Wallace MC, Mior SA. Pancoast tumor: a case report. *J Can Chiropr Assoc*. 1993; 37(4):214-20.
11. Phillips K, Walsh GL. Posterior approach to superior sulcus tumors. In: Patterson GA. *Pearson's thoracic and esophageal surgery*. 3rd ed. Philadelphia: Churchill Livingstone; 2008. pp: 923-32.
12. Calabek B, Meng S, Pollanz S, Klepetko W, Hoetzenecker K, Oberndorfer F, et al. A Case of Pancoast Tumor with Unusual Presentation. *J Brachial Plex Peripher Nerve Inj*. 2015; 10(01): e53-e56. eCollection 2015.