

# CASE REPORT

## Neonatal ascending aorta thrombosis: A case report

Mohammad Nasir Hematin<sup>1</sup>, Mahmood Hosseinzadeh-Maleki<sup>2</sup>, Reza Shabanian<sup>3</sup>,  
Mohammad Ali Navabi<sup>4</sup>, Forod Salehi<sup>2✉</sup>

<sup>1</sup> Assistant Professor of Pediatric Cardiology, Amir Hospital, Semnan University of Medical Sciences, Semnan, Iran.

<sup>2</sup> Birjand CardioVascular Diseases Research Center, Birjand University of Medical Sciences, Birjand, Iran

<sup>3</sup> Assistant Professor of pediatric cardiology, MarkaztebbiKodakan Hospital, Tehran University of Medical Sciences, Tehran, Iran.

<sup>4</sup> Associate Professor of Cardiac Surgery, MarkaztebbiKodakan Hospital, Tehran University of Medical Sciences, Tehran, Iran.

Received: October 14, 2016

Revised: April 29, 2017

Accepted: May 23, 2017

### Abstract

Thrombotic events are very unusual in neonatal period. This congenital anomaly may be caused by certain risk factors such as polycythemia, perinatal asphyxia, septicemia, maternal diabetes, dehydration, and low cardiac output, or it may occur upon catheterization of central lines. A 20-day-old neonate was referred to our ward with primary signs of hypertrophic cardiomyopathy (HCM). Echocardiography and CT-angiography were performed to find stenosis or no stenosis of aortic valve, which showed a great mass into the ascending aorta. This mass was resected and removed successfully and thereafter the aortic arch was repaired. There was no prothrombic disorder in his family history.

**Key Words:** Neonatal, Hypertrophic cardiomyopathy, Thrombosis, Echocardiography, Aorta

### Introduction

Arterial thromboses are less frequent than venous ones. They are more prevalent in cerebral, iliac and femoral vessels, but occur very rarely in the aorta (1). Mostly, aortic thrombosis has been reported following catheterization of umbilical artery and involvement of the descending aorta and renal arteries (2). Reports about ascending aorta and aortic arch are very rare. Because of the rarity of the disease, the pathogenesis information is limited (2). Several other risk factors associated with arterial thrombosis include deficiency of maternal antithrombin III and proteins S and C, complications of umbilical artery catheterization, maternal diabetes, and dilated cardiomyopathy

(DMP)(2). Infantile arterial thrombosis may present initially as congenital heart disorder, especially aortic stenosis and coarctation (3).

Regardless of treatment, mortality and morbidity rates of these patients are high (1). We describe and report our recent experience in the diagnosis and treatment of a neonate in this condition.

### Cases

A 20-day male patient presented in our hospital with complications of respiratory distress, jaundice, murmur, and pulselessness in all extremities. In his history, the patient was born at the end of 38th gestational week with a birth weight of 3600 grams by normal vaginal delivery

©2016 Journal of Surgery and Trauma

Tel: +985632381203

Fax: +985632440488

Po Bax 97175-379

Email: jsurgery@bums.ac.ir



✉ Correspondence to:

Forod Salehi, Birjand CardioVascular Diseases Research Center, Assistant Professor of pediatric cardiology, Vali-Asr Hospital, Birjand University of Medical Sciences, Birjand, Iran; Telephone Number: +989151630556 Email Address: Salehiforod@gmail.com

from first pregnancy of a 25-year-old mother.

On physical examination, his general condition was characterized by poor perfusion, normal respiratory sounds, and palpable liver 1.5-2 cm in the mid-clavicular line. Arterial pulses were not palpable in the extremities. The blood pressure was found to be 86/64mmHg and respiratory rate was 55 per minute. So, we suspected interrupted aorta arch or severe coarctation of the aorta (table 1).

Electrocardiographic findings showed normal sinus rhythm, right axis, biventricular hypertrophy and ischemic-type repolarization alterations. Chest x-ray reported high cardiac shadow with a cardiothoracic ratio of 0.8 (normal values less than 0.60) and normal pulmonary vascular markings.

Echocardiography revealed left ventricular dysfunction, large patent ductus arteriosus (PDA), hypertrophic cardiomyopathy (HCM), a sub-occluding mass in the aortic arch, and a

pedunculated, irregular and mobile mass with measurements of approximately 25×5×5 mm attached to the posterior aortic wall not too close to the aortic valve. The echocardiography did not show any intracardiac thrombi (Fig. 1).

Thrombus was strongly suspected and confirmed by cardiac CT angiography (Fig. 2). In the surgery, a large amount of occluding thrombus was removed, ascending aorta was repaired with autologous path, and the patent ductus arteriosus was ligated. Initially, perfusion and blood pressure were good, but two hours after operation, he died suddenly. At pathology, a calcified thrombus was found in the ascending aorta, partially obstructing the orifices of the ascending aorta (Fig. 3). Laboratory studies showed no evidence of sepsis, maternal diabetes or maternal antithrombin-III deficiency, no congenital heart disease with polycythemia, dehydration, or iatrogenesis.

Table 1: Laboratory data

ABG <sup>1</sup>	TBG <sup>2</sup>	Coom <sup>3</sup>	CBC <sup>4</sup>	LFT <sup>5</sup>	PT &PTT <sup>6</sup>	B/C <sup>7</sup>	AFP <sup>8</sup>	Anti-Rho <sup>9</sup>	TORCH <sup>10</sup>
pH 7.29)	8.45	negati ve	WBC: 7990/mm3 Hb: 15.1 mg/dL Hct: 45%; Plt: 316 000/mm3	Aspartate aminotransferase:25 Alanine aminotransferase:31	14,37	negative	14000 ng/ml	negative	negative

Arterial Blood Gas<sup>1</sup>, Total bilirubinemia<sup>2</sup>, direct Coombs test<sup>3</sup>, Cell Blood Count<sup>4</sup>: (white blood cells: WBC; hemoglobin: Hb; hematocrit: Hct; platelets: plt), liver enzyme level<sup>5</sup>: prothrombin activity and activated partial thromboplastin time<sup>6</sup>, blood culture<sup>7</sup>, Serum alpha phytoprotein<sup>8</sup>, Anti-Rho=lupus anticoagulant<sup>9</sup>, TORCH study<sup>10</sup>(toxoplasmosis, cytomegalovirus and rubella)

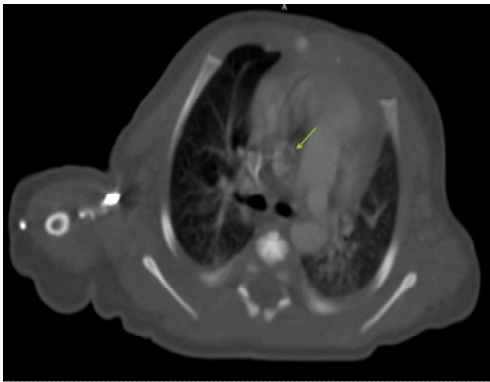


Figure 2: CT angiography with contrast confirmed the aortic mass.

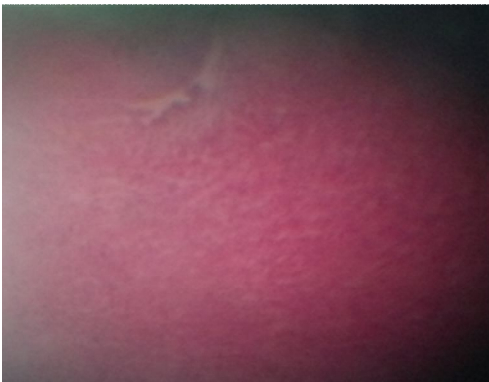


Figure 3: Microscopic view of aortic thrombosis

## Discussion

Infants are at high risk of thromboembolic events due to the lack of complete development of the coagulation system (4). Almost 30-40% of arterial thrombosis cases are created in the aorta (5). Involvement of the aorta influences its arising arteries such as coronary arteries (6). According to a new investigation, only 21 cases of this anomaly have been reported, which are associated with 60% mortality (3).

Symptoms of thrombosis in aorta can be similar to aortic coarctation (7). Two-dimensional echocardiography provides a safe, noninvasive technique for early detection of this disorder, and Doppler echocardiography is the most important diagnostic instrument, ruling out differential diagnosis. While CT angiography and MR angiography are very helpful, there is no single opinion about treatment of aortic thrombosis. Surgical or medical treatment is the first line of rescue for the patient (8). Hence, relation of risk or benefit of management must be determined specifically for each patient. In these patients with no ischemic and life- or organ-threatening signs, LMWH (low molecule weight heparin) is advised as the standard management. In other cases, however, surgical treatment has been advised (9).

In Neal et al's study, 80% of the patients received anticoagulant treatment out of whom 75% improved by thrombolytic method and 67% by surgery (9).

## Conclusions

Aortic thrombosis is a rare and often fatal condition with controversial management. At present, there is no single guideline for treatment of these diseases and future studies are needed to select appropriate therapeutic approach to this condition.

## Acknowledgments

The authors thank NICU head nurse of the pediatrics medical center.

## Conflict of interest

The authors declare no conflict of interest.

## References

1. Gürsu HA, Varan B, Oktay A, Özkan M. A case of neonatal arterial thrombosis mimicking interrupted aortic arch. *Turk Pediatri Ars/Türk Pediatri Arşivi*. 2015 Jun;50(2):118.
2. Saracco P, Parodi E, Fabris C, Cecinati V, Molinari AC, Giordano P. Management and investigation of neonatal thromboembolic events: genetic and acquired risk factors. *Thromb Res*. 2009 Apr 30;123(6):805-9.
3. Wieland I, Jack T, Seidemann K, Boehne M, Schmidt F, Happel CM, Koeditz H, Bertram H, Sasse M. Neonatal aortic arch thrombosis: analysis of thrombophilic risk factors and prognosis. *Cardiol Young*. 2014 Feb 1;24(01):33-9.
4. Ignjatovic V, Mertyn E, Monagle P. The coagulation system in children: developmental and pathophysiological considerations. In *Seminars in thrombosis and hemostasis 2011 Oct (Vol. 37, No. 07, pp. 723-729)*. © Thieme Medical Publishers.
5. Monagle P, Newall F, Barnes C, Savoia H, Campbell J, Wallace T, Crock C. Arterial thromboembolic disease: A single-centre case series study. *J Paediatr Child Health*. 2008 Jan 1;44(1-2):28-32.
6. Salehi F, Ahmadi B, Zaherara M, Riasi H. Coronary Artery Patterns in Neonates with Transposition of the Great Arteries in Tehran. *J Mazandaran Univ Med Sci*. 2015 Feb 15;24(121):368-73.
7. Nagel K, Tuckuviene R, Paes B, Chan AK. Neonatal aortic thrombosis: a comprehensive review. *Klin Padiatr*. 2010 May;222(03):134-9.
8. Kawahira Y, Kishimoto H, Iio M, Ikawa S, Kume Y, Inamura N, Matushita T, Maeno T, Nakada T. Spontaneous aortic thrombosis in a neonate with multiple thrombi in the main branches of the abdominal aorta. *Cardiovasc Surg*. 1995 Apr 1;3(2):219-21.
9. Lofù I, Di Mauro A, Di Coste A, Scalini E, Basile V, Codazzi D, Laforgia N, Manzionna M. Idiopathic neonatal aortic arch thrombosis: a case report. *EMBJ*. 2014 Jan 1.