

CASE REPORT

Torsades de pointes: Should ECG be taken from all patients before surgery? A case report

Nahid Azdaki¹, Hamidreza Mashreghimoghaddam¹✉, Marjan Farzad¹,
Toba Kazemi¹

¹Cardiovascular Diseases Research Center, Birjand University of Medical Sciences, Birjand, Iran.

Received: February 20, 2017 Revised: April 3, 2017 Accepted: April 9, 2017

Abstract

Torsades de pointes is a rare but potentially lethal arrhythmia which mainly occurs in the setting of a prolonged QT interval. ECG is a reliable tool to detect such abnormalities, routinely taken from all patients over 40 who undergo surgery.

We describe the case of a 35-year-old woman with torsades de points arrhythmia after hysterectomy surgery. Most likely, our patients had long QT syndrome which has not already been detected.

Surgery can elicit both acquired and unknown congenital long QT syndrome. Preoperative ECG is recommended even for people under 40 years to detect unknown congenital long QT syndrome.

Key Words: Long QT Syndrome, Torsade de Pointes, Electrocardiogram

Introduction

Torsade de pointes is an arrhythmia which occurs in the setting of a prolonged QT interval, T-wave abnormality, or increased U-wave amplitude (1). TdP episodes may lead to syncope, pseudoseizure, or more lethal forms such as ventricular fibrillation. Abnormal cardiac repolarization triggers tachyarrhythmias, such as torsade de pointes, which can result in sudden cardiac death. Abnormal cardiac repolarization can be identified on the electrocardiogram as a prolonged QT interval (2-3). Typically, a QT interval <440msec is considered normal. QT prolongation can either be inherited, as in the long QT syndrome, or acquired. Acquired QT prolongation is often caused by drugs which increase the risk of torsade de pointes and sudden cardiac death (4). Stress, hypothermia, and electrolyte disturbances, particularly hypokalemia and hypomagnesemia, are causal conditions for QT prolongation. They are common during major

surgery and may lead to torsade de pointes. This report describes torsade de pointes in a patient after hysterectomy.

Cases

A 35-year-old woman was referred to the operating room at Valiasr Hospital affiliated with Birjand University of Medical Sciences for hysterectomy. During the operation, she had bigeminal PVC which was managed by 75mg IV bolus of lidocaine and 1gr of magnesium sulfate. The patient was transferred to the ward with sinus rhythm. At the ward, the patient re-experienced arrhythmia in the form of torsade de pointes and subsequently cardiac arrest. She underwent cardiopulmonary resuscitation, drug management of 2gr magnesium sulfate, and application of 50 J DC-shock. The patient was transferred to the CCU after heart consulting. She was under careful monitoring and laboratory studies. ECG was taken daily for 6 days. She had ECG with normal sinus

©2016 Journal of Surgery and Trauma

Tel: +985614443041 (5533)

Fax: +985614440488

Po Bax 97175-379

Email: jsurgery@bums.ac.ir



✉ Correspondence to:

Hamidreza Mashreghimoghaddam, Cardiovascular Diseases Research Center, Birjand University of Medical Sciences, Birjand, Iran;

Telephone Number: 0989151611978

Email Address: hamidmashreghi@yahoo.com

rhythm, Tinvert (V1-V6) and QTc=540msec (Fig. 1a). The patient's echocardiography was normal. Blood count and serum electrolytes were within normal ranges.

Anesthesia had been performed with Nesdonal 300 mg intravenously (IV), Propofol 200 mg of 1% solution (2 Ampules IV), Fentanyl 2mcg/kg (IV), Morphine 6mg (IV), Midazolam 1mg (IV) and Atracurium 30mg (IV). There was no history of hypertension, diabetes, lung diseases, gastrointestinal and ischemic heart diseases in the past medical history of the patient or her family. There was no history of sudden death in her family either. The patient was addicted to opium.

Discussion

We described a patient with torsade de pointes arrhythmia after hysterectomy surgery. TdP is a form of polymorphic ventricular tachycardia, predominantly occurring in the setting of a prolonged QT interval, Twave abnormality or increased U-wave amplitude (1). It often precedes ventricular fibrillation. Electrocardiographically, TdP is a pattern of continuously changing

morphology of the QRS complexes twisting around an imaginary baseline (Fig. 1b).

The QT interval represents the depolarization and repolarization of the ventricles (5-6). Prolongation of the QT interval is caused by an increase in action potential duration of ventricular myocytes (6). A QT interval can be prolonged congenitally or acquired. Congenital long QT syndrome (LQTS) is subdivided into 10 genotypes. Acquired QT prolongation is often caused by drugs. Drug-induced QTc interval prolongation increases the risk for torsade de pointes and subsequent sudden cardiac death (4). In addition, conditions conducive for QTc prolongation such as stress, hypothermia and electrolyte disturbances, particularly hypokalemia and hypomagnesemia, are common during major surgery.

Our patients had received neither medications that induce QTc interval prolongation nor electrolyte imbalance. Our patient was addicted and had a history of taking methadone. Methadone is associated with QTc interval prolongation (7), but history showed that methadone had not been taken by the patient since previous months.

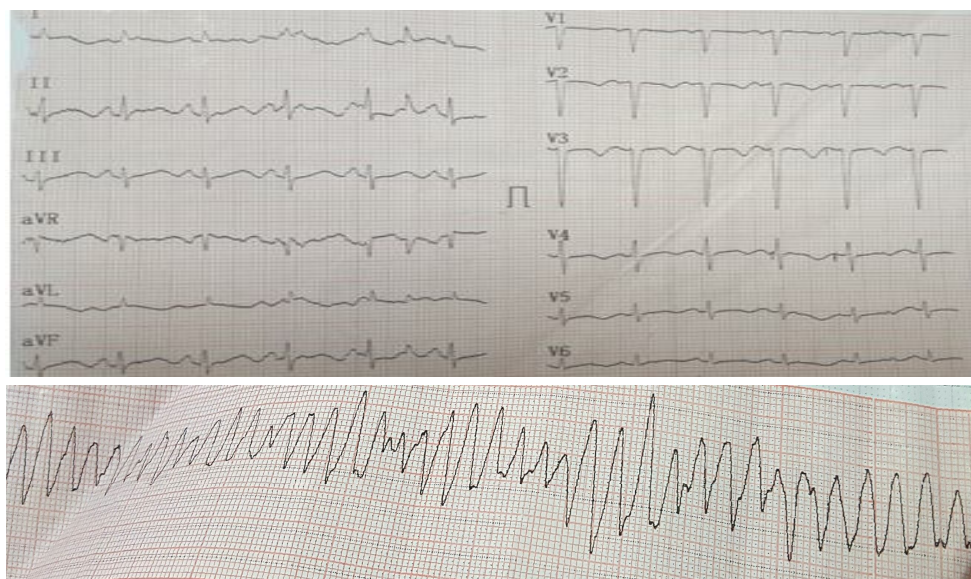


Figure 1: Postoperative electrocardiographic (ECG) recordings: a) Postoperative ECG. Sinus rhythm, Tinvert (V1-V6) with QT prolongation (QTc=540msec); b) Torsade de pointes episode

Conclusions

As ECG is a reliable tool to detect abnormalities that may lead to malignant tachyarrhythmias and surgery potentially elicits arrhythmia, preoperative ECG and heart consulting for all patients under 40 years old in case of unknown congenital long QT syndrome is recommended. The authors suggest that ECG should be taken from all patients under 40 years who have a history of methadone taking before surgery.

Acknowledgements

Special thanks to the research deputy of Birjand University of Medical Sciences, the clinical research center of Valiasr Hospital, and all personnel at Birjand University of Medical Sciences, Iran.

Conflict of interest

The authors declare no conflict of interest.

References

1. Gowda R, Khan I, Wilbur S, Vasavada B, Sacchi T. Torsade de pointes: the clinical considerations. *Int J Cardiol.* 2004;96:1-6.
2. Roden DM. Long-QT Syndrome. *N Engl J Med.* 2008;358:169-76. [PubMed: 18184962].
3. Pollard CE, Abi Gerges N, Bridgland-Taylor MH, Easter A, Hammond TG, Valentin JP. An introduction to QT interval prolongation and non-clinical approaches to assessing and reducing risk. *Br J Pharmacol.* 2010;159:12-21. [PubMed: 20141516].
4. Heist EK, Ruskin JN. Drug-Induced Arrhythmia. *Circulation.* 2010;122:1426-35. [PubMed: 20921449].
5. Roden DM, Viswanathan PC. Genetics of acquired long QT syndrome. *J Clin Invest.* 2005;115:2025-32.
6. Antzelevitch C. Ionic, molecular, and cellular bases of QT-interval prolongation and torsade de pointes. *Europace.* 2007;9(suppl 4):iv4-iv15.
7. Vieweg WVR, Hasnain M, Howland RH, Clausen T, Koneru JN, Kogut C, et al. Methadone QTc interval prolongation and torsade de pointes: Case reports offer the best understanding of this problem. *Therapeutic Advances in Psychopharmacology.* 2013;3(4):219-32.